Case scenarios in Surgery

Dr.M.RAMULA M.S.,D.G.O

30.7.2020

CASE 1: Lump in the groin

- History: A 51-year-old woman presents to the emergency department with a painful right groin. She reports lower abdominal distension and has vomited twice on the way to the hospital. She has passed flatus but has not opened her bowels since yesterday. She is otherwise fit and well and well built. She lives with her husband and four children.
- Examination: On examination she appears unwell. Her blood pressure is 106/70mmHg and the pulse rate is 108/min. She is febrile with a temperature of 38.0°C. The abdomen is tender, particularly in the right iliac fossa, and there is marked lower abdominal distension. There is a small swelling in the right groin, which is originating below and lateral to the pubic tubercle. The lump is irreducible and no cough impulse is present. Digital rectal examination is unremarkable and bowel sounds are hyperactive.

Investigations

Plain X-ray Abdomen Erect

Blood investigations

Haemoglobin : 14.1g/dL
White cell count 18.0 × 109/L
Platelets 361 × 109/L
Sodium 133mmol/L 135–145mmol/L
Potassium 3.3mmol/L 3.5–5.0mmol/L
Urea 6.1mmol/L 2.5–6.7mmol/L
Creatinine 63µmol/L 44–80µmol/L
Amylase 75 IU/L 0–99 IU/L

Questions

- What is the diagnosis?
- Are there any patients at particular risk of developing this condition?
- What is the significance of the right iliac fossa pain in this setting?
- How will you manage?

Answers

- This woman has a right-sided femoral hernia. The neck of the femoral hernia lies below and lateral to the pubic tubercle, differentiating it from an inguinal hernia, which lies above and medial to the pubic tubercle.
- The x-ray shows small-bowel dilation as a result of obstruction due to trapped small bowel in the hernia sac.
- The high white cell count, temperature and tenderness may indicate strangulation of the hernia contents.
- The rigid borders of the femoral canal make strangulation more likely than in inguinal hernias.

Surgical Anatomy

- Anteriorly: inguinal ligament
- Posteriorly: superior ramus of the pubis and pectineus muscle
- Medially: body of pubis, pubic part of the inguinal ligament
- Laterally: femoral vein

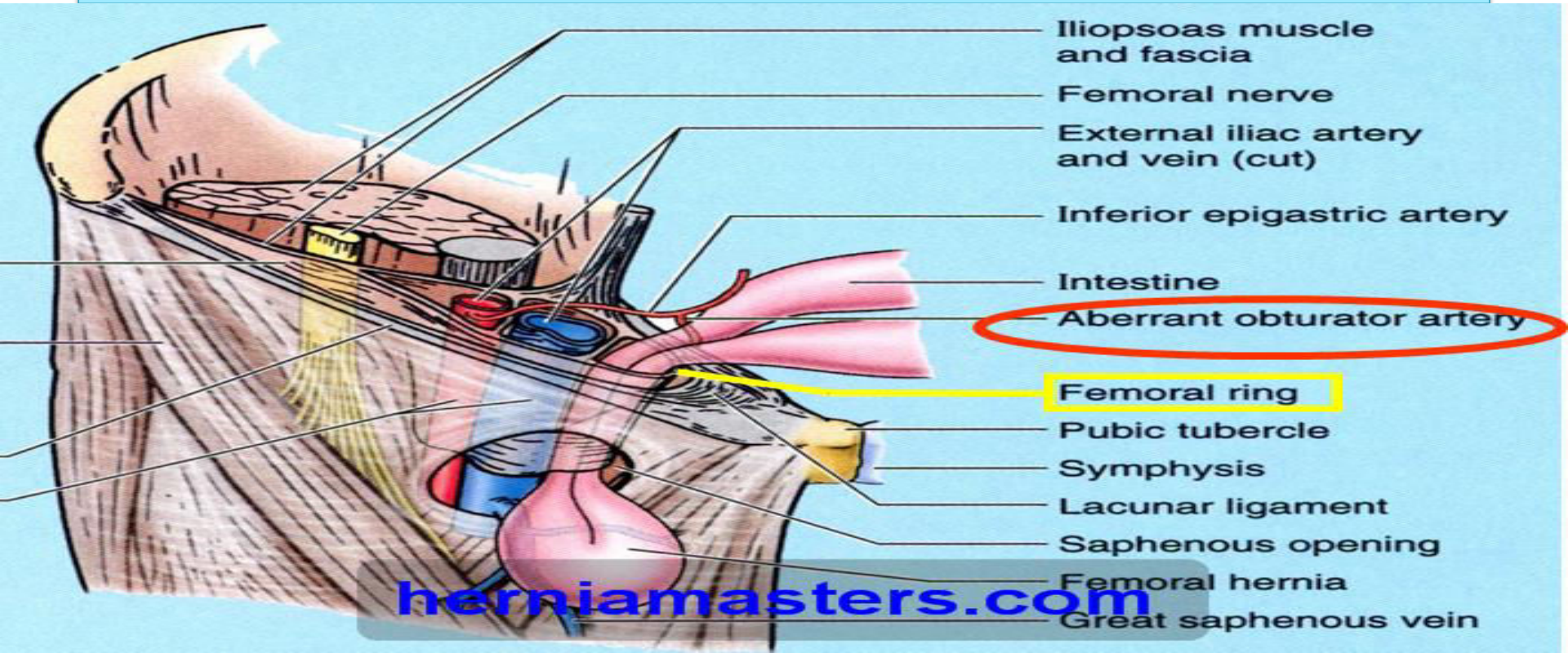

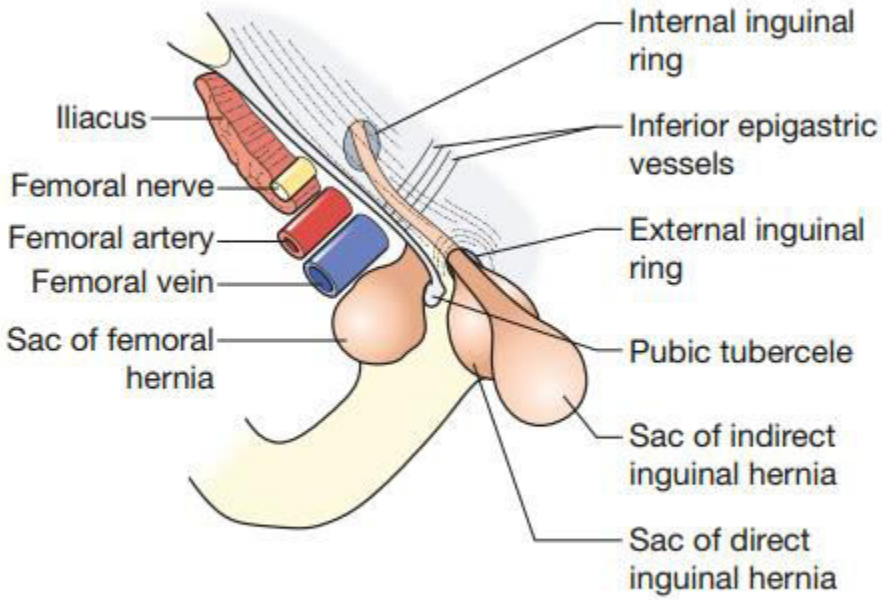

Figure 60.10 The close relationships of direct inguinal, indirect inguinal and femoral hernias.

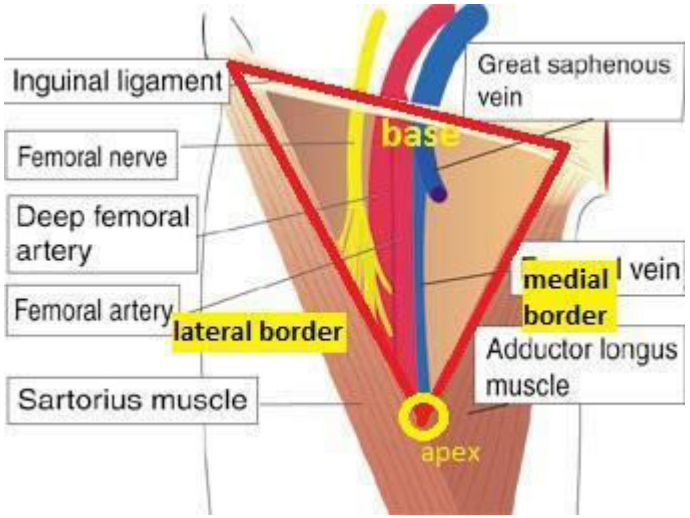

Coverings of the sac of femoral hernia

- Skin
- Superficial fascia
- Cribriform fascia
- Anterior layer of femoral sheath
- Fatty contents of femoral canal
- Femoral septum
- Peritoneum

Differential diagnosis

- *An inguinal hernia.*
- *A saphena varix.*
- *An enlarged femoral lymph node.*
- *Lipoma.*
- *A femoral aneurysm.*
- *A psoas abscess.*
- *A distended psoas bursa.*
- *Rupture of the adductor longus with haematoma formation.*

Complications

1. Irreducibility
2. Obstruction
3. Strangulation is a surgical emergency

- Risk of obstruction and strangulation is very high in femoral hernia, paraumblical hernia and indirect inguinal hernia with narrow neck

Management

- The patient should be kept NPO, and intravenous fluids and antibiotics begun.
- A nasogastric tube should be passed and bloods taken in preparation for theatre.
- The patient taken for urgent surgery to reduce and repair the hernia, with careful inspection of the hernia sac contents.
- If the bowel is infarcted, it will need to be resected.

TREATMENT

3 classical approach :

i. **Low approach (Lockwood)**

below the inguinal ligament

ii. **Inguinal approach (Lotheissen)**

through inguinal canal

iii. **High approach (McEvedy)**

mainly above the inguinal canal

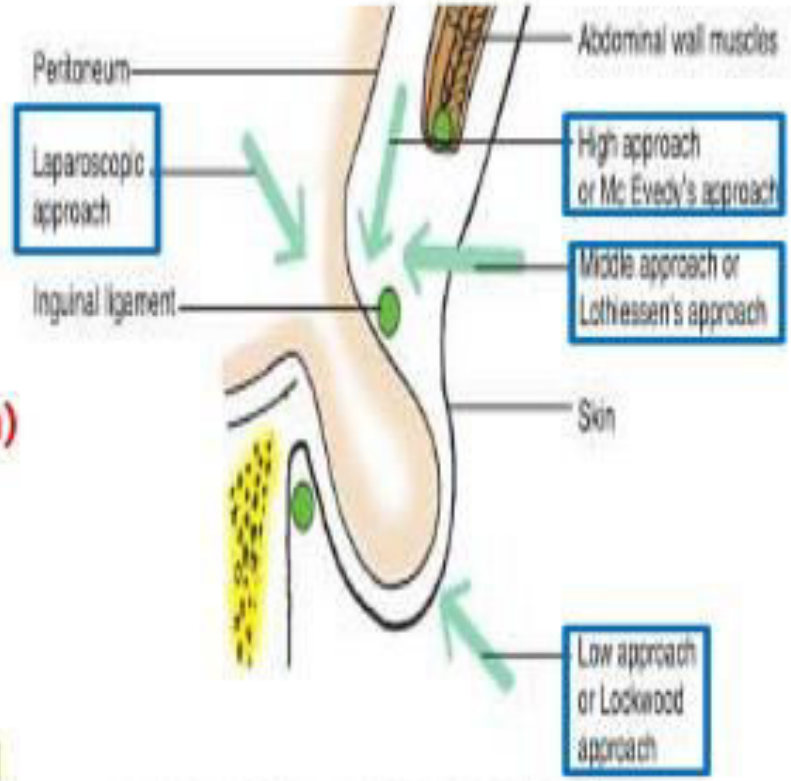

Fig. 19.99. Various operative approaches of femoral hernia.

*some cases can be managed **laparoscopically**

Femoral Hernia-Complications Of Surgery

- Seroma/ Hematoma
- Urinary retention
- Wound infection
- Recurrence
- Bleeding from aberrant obturator artery
- Chronic neuralgic pain due to nerve injury or entrapment

- **Richter's hernia**
  - Frequent complication of femoral hernia
  - Only part of circumference of bowel enclosed in the hernia sac which may become gangrenous
  - Clinically; abdominal symptoms of IO but with no constipation.

الدكتور
سمير الصفار

Keep Up
The
Good
Work

Case 2: Small-bowel anomaly

- History
- A 14-year-old boy presented to the emergency department with a 24-h history of increasing abdominal pain. The pain localized to the right iliac fossa and a diagnosis of acute appendicitis was made. At operation, the appendix was found to be normal and the anomaly shown

Questions

- What is the diagnosis?
- What are the characteristics of this anomaly?
- How can this present?
- How would you deal with this intra operative finding?

Meckel's Diverticulum

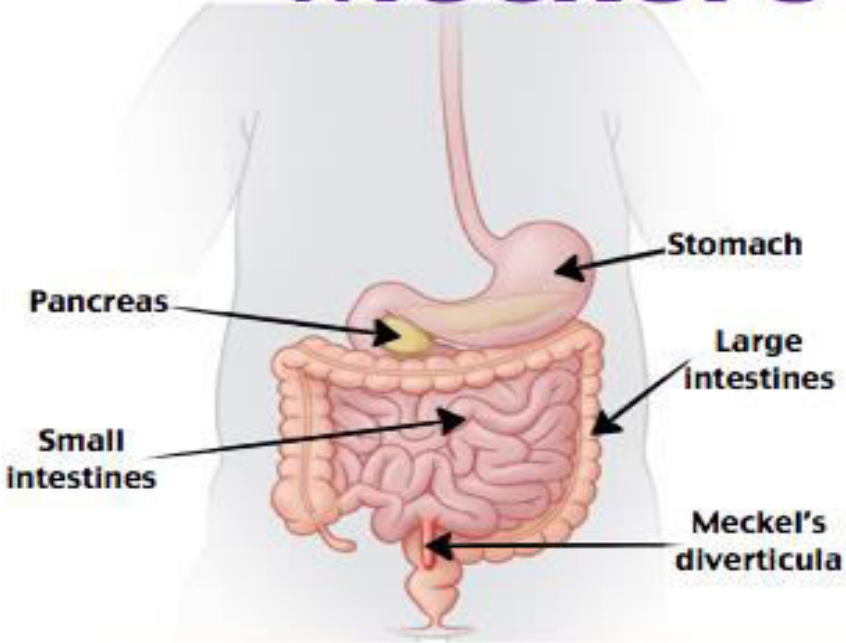

Clinical

- **True** diverticula of **all 3 layers** of the small intestines
- Caused by **incomplete obliteration** of the **vitelline duct**
- **Rule of 2s**: 2-years-old, 2 ft from ileocecal valve, 2 in long, 2% of population
- Usually asymptomatic
- **Painless bleeding** due to ulcer caused by **heterotopic gastric tissue**
- Obstruction caused by intussusception, volvulus, hernia

Diagnosis

- Nuclear medicine scan (**99m technetium pertechnetate - Meckel's scan**)

TRUE/FALSE

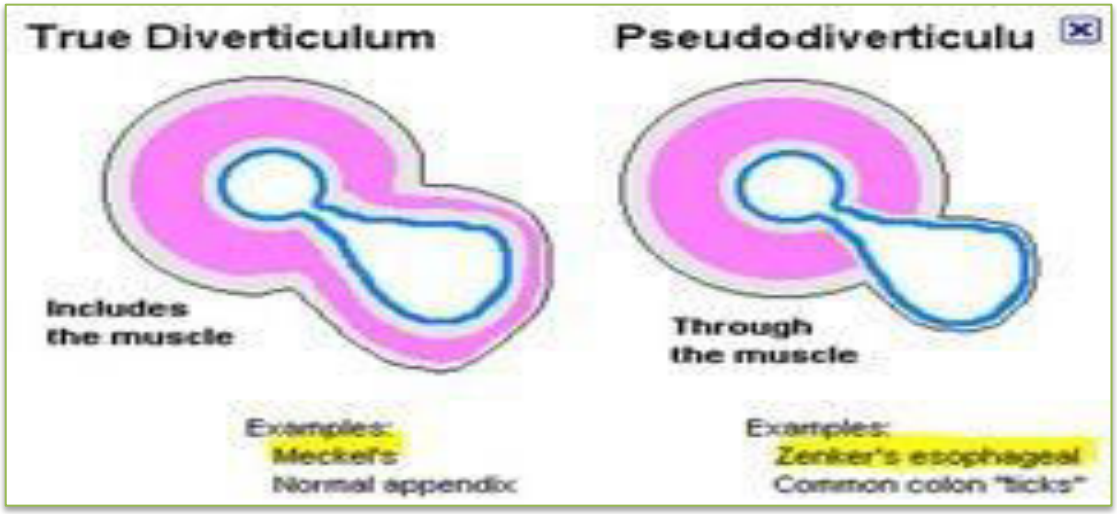
True Diverticulum
Pseudodiverticulu
Includes
the muscle
Through
the muscle
Examples:
Meckel's
Normal appendix
Examples:
Zenker's esophageal
Common colon "ticks"

Meckel's diverticulum

- **located on the anti-mesenteric border of a segment of ileum.**
- **This is a remnant of the omphalomesenteric duct.**

- A Meckel's diverticulum may be lined by small-intestinal, colonic or gastric mucosa, and it may contain aberrant pancreatic tissue.

- The mode of presentation may be:
- Inflammation and perforation of the diverticulum presenting with abdominal pain
- and peritonitis, ***mimicking acute appendicitis***
- ***Rectal bleeding*** from peptic ulceration caused by acid secretion from the ectopic gastric mucosa
- Intestinal obstruction from ***intussusception o***r entrapment of the bowel in a mesodiverticular band or a fibrous band that may connect the apex of the diverticulum to the umbilicus or anterior abdominal wall
- Tumours may also develop inside a Meckel's diverticulum.
- A symptomless diverticulum that is an incidental finding at laparotomy should not be excised.

INVESTIGATION

MECKEL'S SCAN

- Meckel's diverticulum = remnant of vitellointestinal duct
- Disease of 2's
- only picks up Meckel's containing gastric mucosa 50%
- 99m-Tc-pertechnetate radioisotope used
  - concentrated mainly by the mucous secretory cells of the stomach

- 85% sensitive
- 95% specific
- Useful in Ix of young patients with GIT bleeding

Meckel s scan

Meckel's Diverticulum Scan

Disease of TWO

- Meckel's diverticulum = Remnant of omphalomesenteric duct
- Common presentation: painless lower GI bleeding in small children
- Imaging:
  - Principle: To detect ectopic gastric mucosa
  - Patient preparation:
    - NPO at least 4 hr.
    - Can perform when bleeding is inactive,
    - Avoid barium / laxatives / endoscope on the day prior the study.
    - Pharmacologic augmentation - cimetidine, ranitidine
  - Radiopharm: Tc-99m pertechnetate IV.
  - Sequential imaging for 1-2 hr.
  - Sensitivity 85%, specificity 95%

Common NM Studies_Part I By J. Sriprapapom

Differential diagnosis

- Intestinal obstruction
- Hematochezia
- Appendicitis
- Intussusception
- Lower GI bleeding
- Angiodysplasias
- Malignancy
- Arteriovenous malformations

Indication for surgery

Incidentally discovered Meckel diverticulum

- Patients younger than 40 years
- Diverticula longer than 2cm
- Diverticula with narrow necks
- Diverticula with fibrous bands
- Suspected ectopic gastric tissue
- Inflamed, thickened diverticula

Treatment

- Symptomatic Meckel's diverticula requires open exploration.
- Resection
  - antimesenteric wedge excision
  - segmental bowel resection with primary closure or anastomosis.
- Laparoscopic dx and mgt also described.
- Minimal morbidity/mortality unless intestinal necrosis occurred

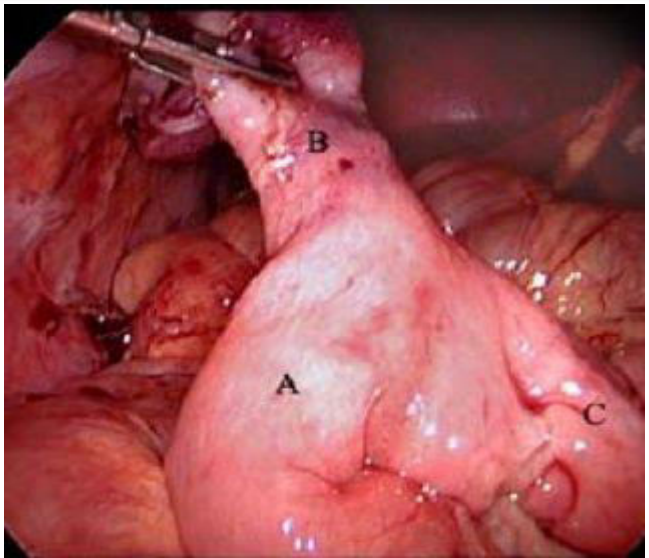

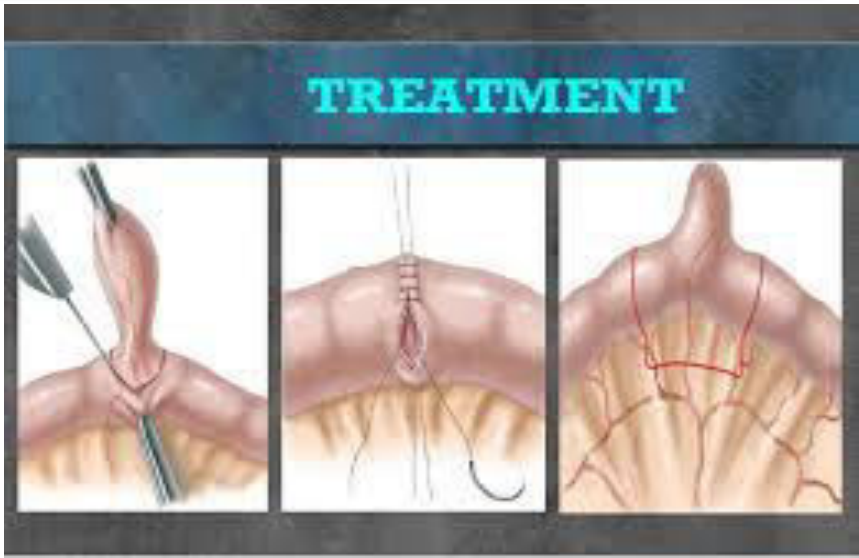


Well Done
High Five
Blingee

3: abdominal distension and pain

- History
- A 70-year-old man has been sent to the emergency department from a nursing home,

complaining of intermittent sharp abdominal pain. He has not opened his bowels for 5 days.. He has a history of chronic constipation. Previous medical history includes chronic obstructive airways disease for which he is on regular inhalers. He is allergic to penicillin and is an ex-smoker.

- Examination
- His blood pressure is 110/74mmHg and the pulse rate is 112/min. His temperature is 37.8°C.

There is gross abdominal distension with tenderness, most marked on the left-hand side.

The abdomen is resonant to percussion and digital rectal examination reveals an empty rectum on auscultation of the chest there is a soft systolic murmur and mild scattered inspiratory wheeze


R

Questions

- What does the abdominal x-ray show?
- What other radiological investigation could be employed if the diagnosis was in doubt?
- How should the patient be managed?
- What is the explanation for the pathology?

ANSWERS

- The x-ray shows a sigmoid volvulus. The sigmoid colon is grossly dilated and has an inverted U-tube shape. The involved bowel wall is usually oedematous and can form a dense central white line on the radiograph.
- On either side, the dilated loops of apposed bowel give the characteristic ‘coffee bean’ sign. X-ray appearances are diagnostic in 70 per cent of patients.
- If there is doubt about the diagnosis, a water-soluble contrast may be helpful in showing a classical ‘bird’s beak’ appearance representing the tapered lumen of the colon.

BIRDS BEAK

IMAGING STUDIES

xray:

coffee bean appearance

barium swallow: bird beak appearance

Barium enema

- massive sigmoid volvulus
  - tapered obstruction at the rectosigmoid junction with a typical bird's-beak deformity

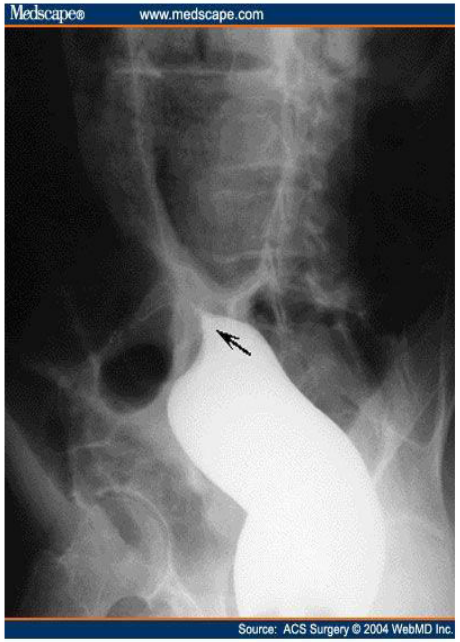

Predisposing causes of sigmoid volvulus are:

1- Band of adhesions.

2- Overloaded pelvic colon.

3- Long pelvic mesocolon.

4- Narrow attachment of pelvic mesocolon.

5- high residue diet and constipation.

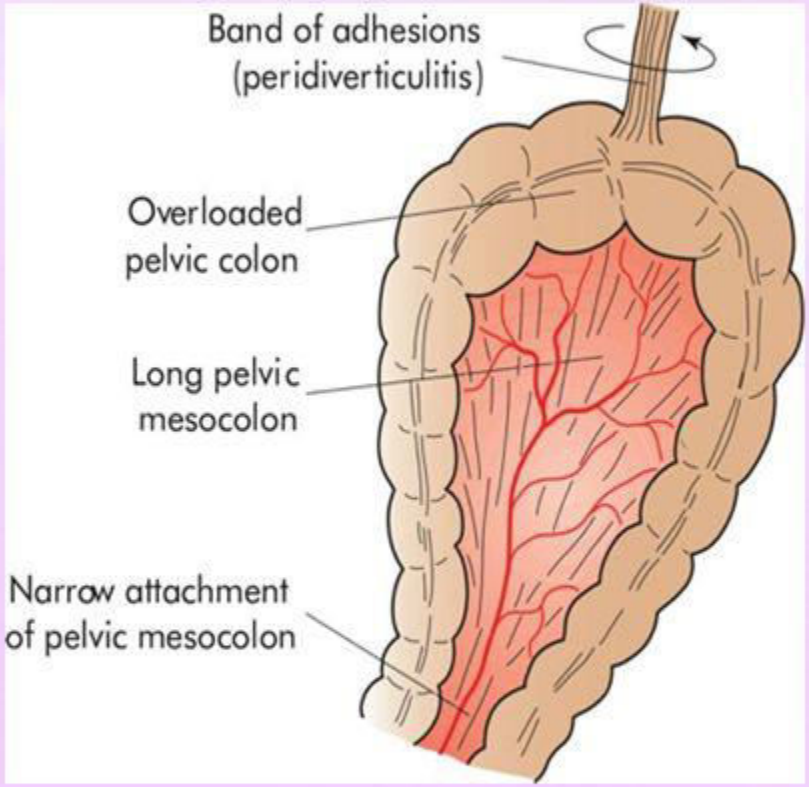

Sigmoid Volvulus

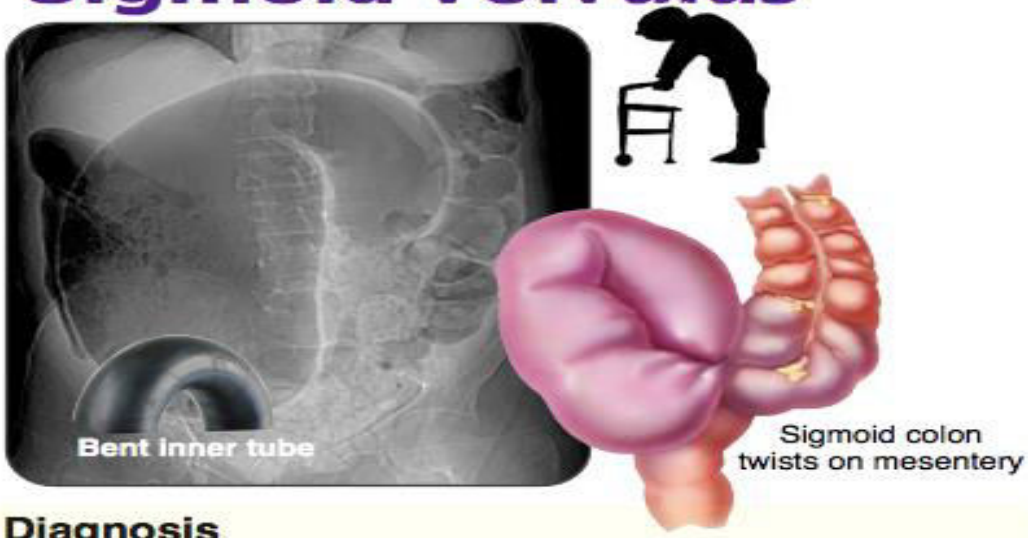

Diagnosis
- Plain film (Low specificity) [U-shaped, bent inner tube]
- Abdominal CT scan
- Contrast enema

Risk factors
- Nursing home patients
- Elderly
- Bed bound
- Chronic constipation

Clinical
- Insidious onset of slowly progressive abdominal pain
- Abdominal distension
- Nausea, constipation
- Vomiting (several days after pain onset)

Management
- Flexible sigmoidoscopy (to reduce volvulus)
- Surgery (to prevent recurrence)

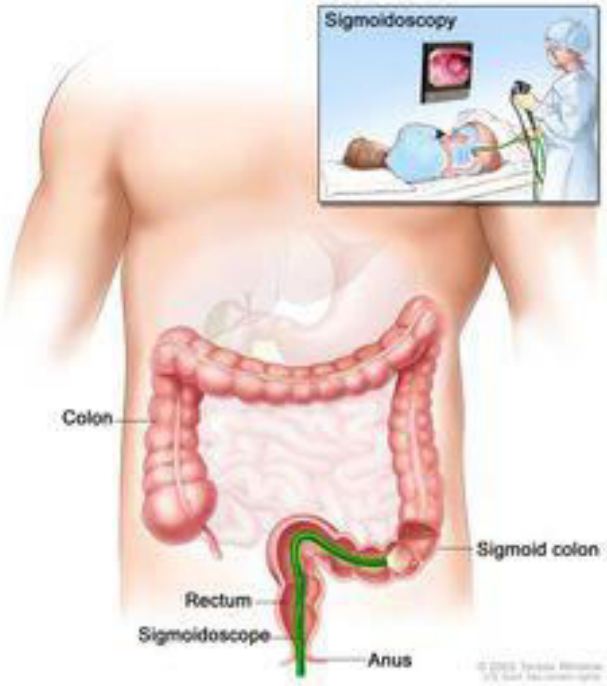

Management

- The flatus tube is left in situ for approximately 48h and is often only a temporary measure.
- Colonoscopy can be used to decompress the bowel and may resolve the volvulus. Urgent laparotomy will be required if decompression is not possible or in cases of suspected gangrene/
- perforation (fever, leucocytosis, peritonism, free air under the diaphragm on erect chest radiography). The patient's fitness for surgery, prognosis and quality of life should be considered
- before proceeding to laparotomy. It may be appropriate to use only conservative treatments in some patients.

Gangrenous sigmoid

Fig. 1: Showing the gangrenous sigmoid volvulus. s

SURGERY

Operative management for sigmoid volvulus

- Elective resection
  - Same admission
- Emergent laparotomy
  - Operation depends on viability of the bowel
    - Resection and anastomosis
    - Hartmann resection
    - Exteriorization resection
    - Detorsion
    - Detorsion with colopexy
    - Percutaneous colostomy
    - Percutaneous sigmoidpexy

Algorithm

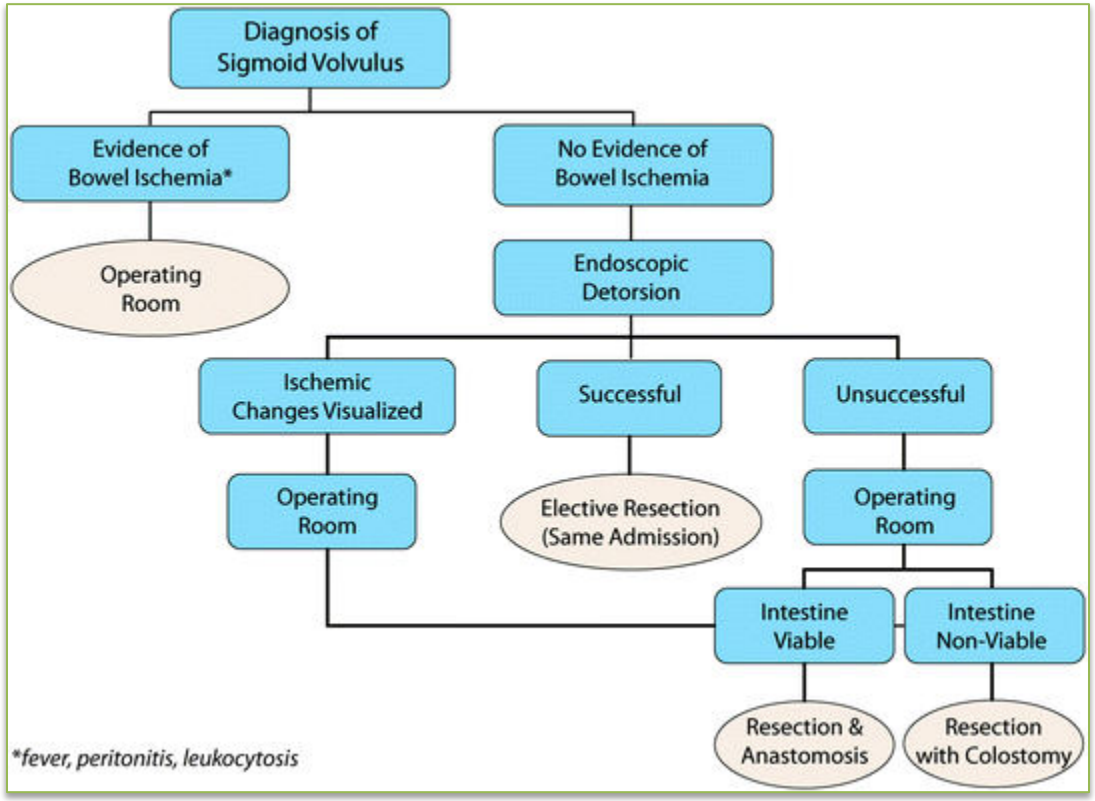
Diagnosis of Sigmoid Volvulus
Evidence of Bowel Ischemia*
No Evidence of Bowel Ischemia
Operating Room
Endoscopic Detorsion
Ischemic Changes Visualized
Successful
Unsuccessful
Operating Room
Elective Resection (Same Admission)
Operating Room
Intestine Viable
Intestine Non-Viable
Resection & Anastomosis
Resection with Colostomy
*fever, peritonitis, leukocytosis

Treatment of sigmoid volvulus

- Keep patient nil by mouth
- Intravenous access and fluids
- Fluid balance monitoring
- Routine bloods and crossmatch
- Erect chest x-ray/abdominal x-ray
- Decompression with rigid sigmoidoscopy and insertion of a flatus tube once the diagnosis is confirmed on abdominal x-ray


Good
Work
Well
Done!

CASE 4: sudden-onset epigastric pain

- History
- A 41-year-old male presents to the emergency department with epigastric pain and vomiting.
- The pain began suddenly 2 h previously, followed by 3–4 episodes of non bilious vomiting. He had been previously fit and well. He is a smoker and Chronic alcoholic
- Examination
- The patient is sweaty and only comfortable while lying still. His blood pressure is 170/90 mmHg, pulse 116/min and temperature 37.5°C. The upper abdomen is tender and rigid on palpation.

Examination

- The patient is febrile with a temperature of 38°C and a pulse rate of 116/min. He is not clinically jaundiced.
- On palpation of the abdomen, there was diffuse tenderness with gaurding and rigidity
- . The urine is clear and rectal examination is normal.
- Xray shown below

X-RAY

INVESTIGATIONS

- Normal
- Haemoglobin 12.0g/dL 11.5–16.0g/dL
- Mean cell volume 86fL 76–96fL
- White cell count 13.2 × 109/L 4.0–11.0 × 109/L
- Platelets 250 × 109/L 150–400 × 109/L
- Sodium 137mmol/L 135–145mmol/L
- Potassium 3.5mmol/L 3.5–5.0mmol/L
- Urea 5mmol/L 2.5–6.7mmol/L
- Creatinine 62µmol/L 44–80µmol/L
- Amylase 250 IU/dL 0–100 IU/dL
- AST 30 IU/L 5–35 IU/L
- GGT 242 IU/L 11–51 IU/L
- Albumin 45g/L 35–50g/L
- Bilirubin 12mmol/L 3–17mmol/L
- Glucose 5mmol/L 3.5–5.5mmol/L
- LDH 84 IU/L 70–250 IU/L
- Total serum calcium 2.35mmol/L 2.12–2.65mmol/L

Questions

- • What is the likely diagnosis?
- • How should this patient be managed?
- • How should this patient be managed after discharge?

Hollow Viscus Perforation

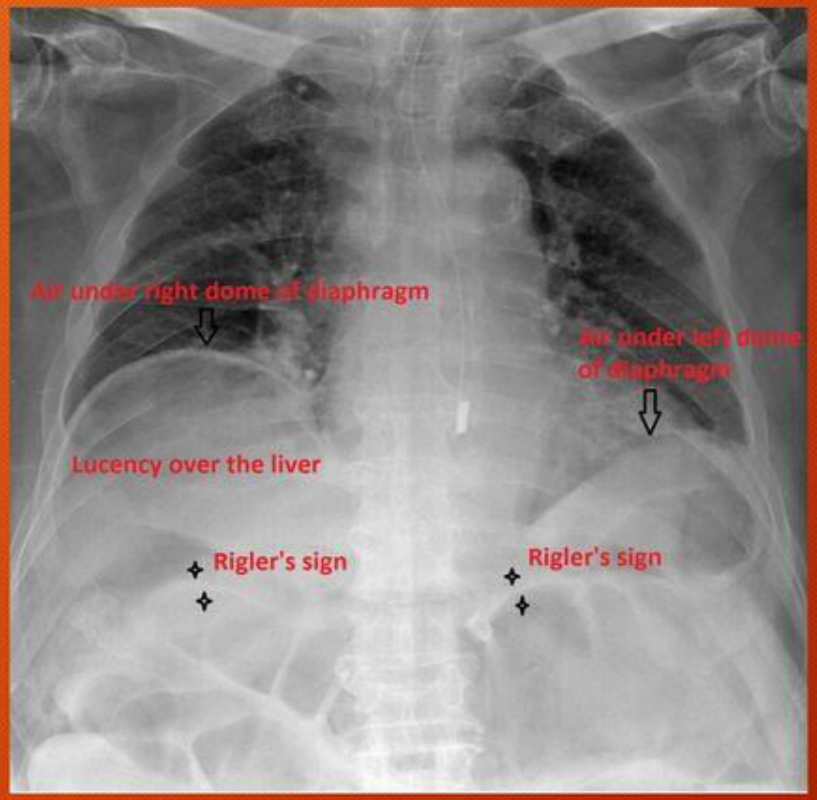

- Double wall sign(Rigler's sign)
- Prominent falciform ligament
- Diagnostic accuracy –user dependent

PNEUMOPERITONEUM

- Pneumoperitoneum refers to the presence of free gas within the peritoneal cavity
- Almost always caused by perforation of hollow viscus.
- Perforated duodenal ulcer is the most frequent cause

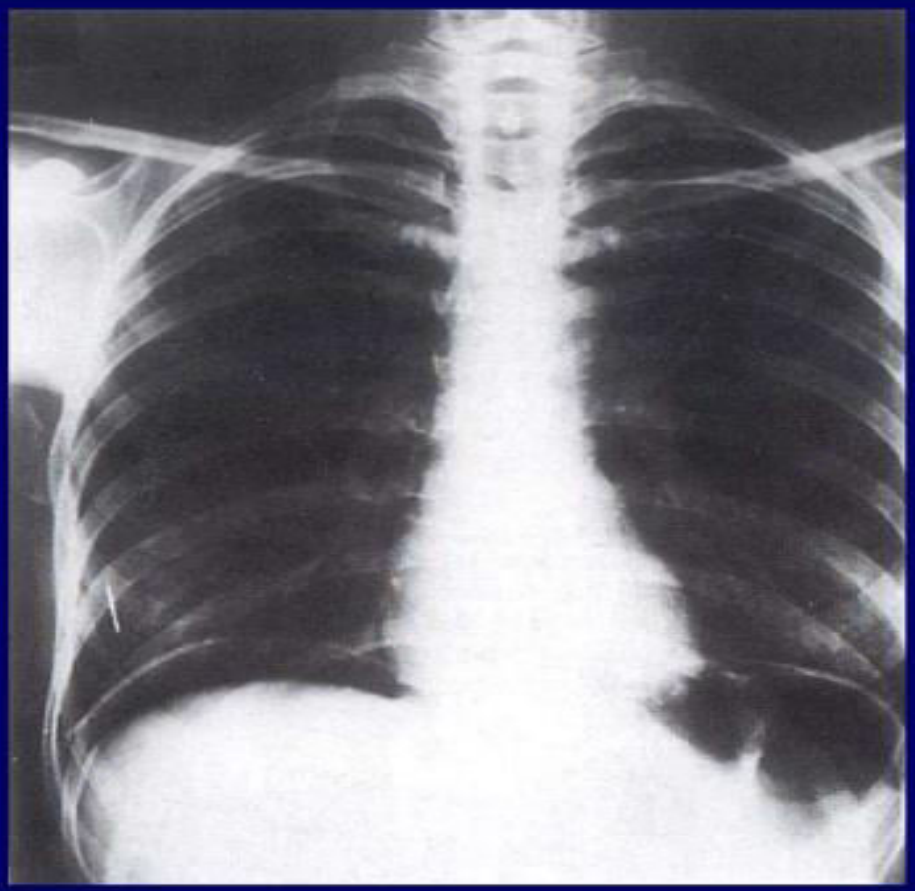

Causes and Pathophysiology of Acute Abdomen

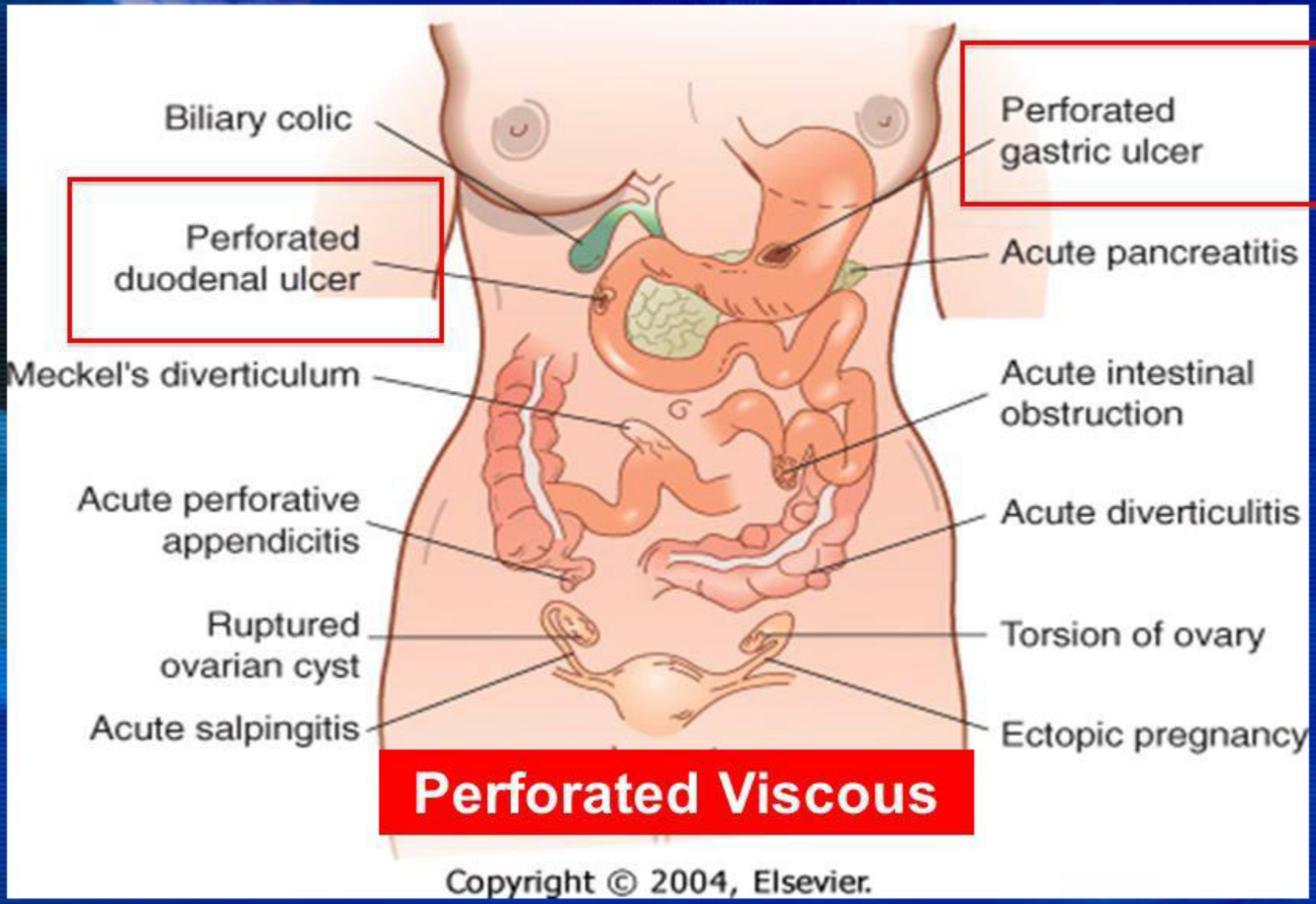

- Formation of dense adhesions between omentum and sites of perforation or inflammation thus facilitates use as patch for duodenal perforation for ulcer disease known as *Graham patch*

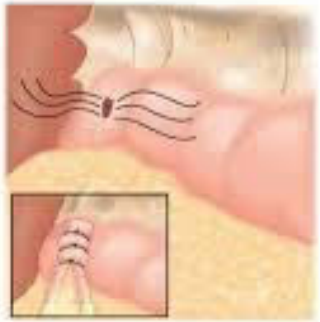

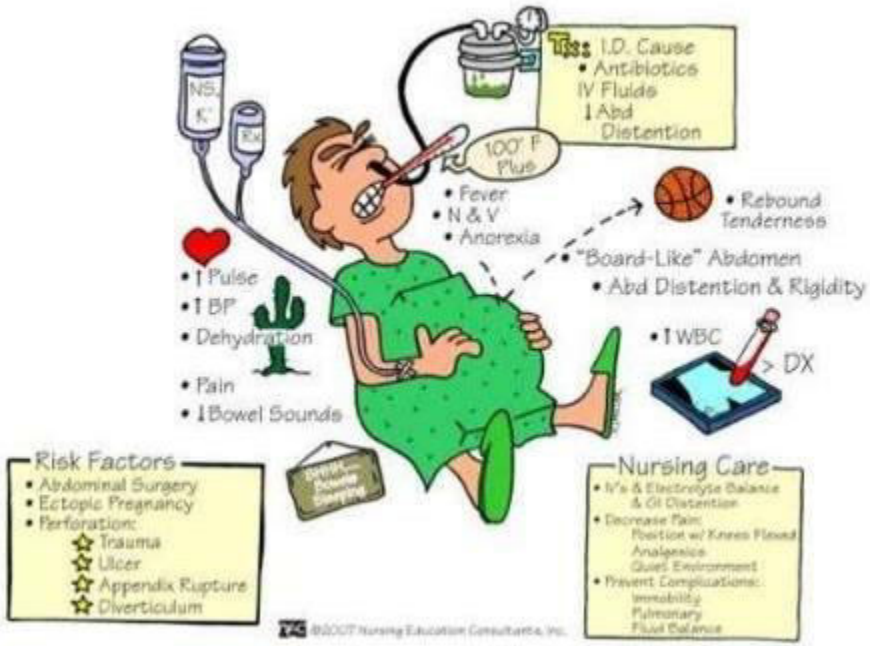

Graham's Omental Patch

- Oversew perforation with omental patch
- Take 1 cm bites either side of ulcer
- Multiple seromuscular 2-0 silk sutures are placed adjacent to the edges of the perforated ulcer.
- A segment of omentum is placed over the perforation, and the sutures are tied down.
- Thorough wash out and irrigation of peritoneal cavity with 0.9% saline

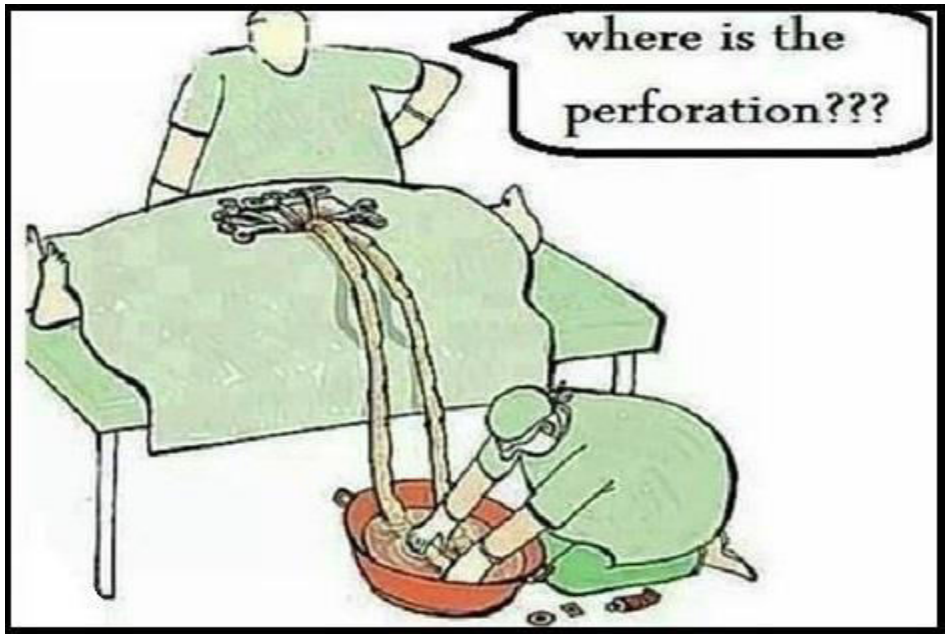

Management

- Kept NPO
- Ryle's tube
- Catheterization with Foley's catheter
- Resuscitated with IV fluids
- IV antibiotics
- Pantoprazole
- Prepared for Exploratory Laparotomy

Following resuscitation, the treatment is principally **surgical**

- Laparotomy
- Laparoscopy

❖ Component

- Thorough peritoneal toilet(remove fluid and food debris)
- Closing the ulcer (omental patch can be placed)
- Vagotomy (recently highly selective vagotomy)
- Systemic antibiotics
- Gastric anti-secretory agents

Follow up

- Postoperatively, patients should be considered for *Helicobacter pylori* eradication therapy and
- Should continue on a proton pump inhibitor
- Refrain from alcohol

5.Ulcer foot

- History
- A 54-year-old insulin-dependent diabetic woman has come to the emergency department complaining of increasing pain in the right foot for the past week. For the past few days she has noticed swelling, redness and dis colouration over the base of the big toe. Her glucose control has been recently reviewed by doctor her insulin regimen changed.
- Examination
- She is afebrile, her pulse is 86/min, her blood pressure is 130/60 mmHg and her blood glucose is 13.2 mmol/L on BM stick testing. Femoral pulses are palpable bilaterally. Palpable femoral & popliteal, but posterior tibial or dorsalis pedis pulses are feebly palpable in the affected limb. The great toe is erythematous with a large fluctuant swelling at the base.

Clinical Presentation

Clinical examination

- This patient has poor diabetic control.
- Examination
- swelling and erythema over the base of the first metatarsal, which may indicate an underlying collection of pus
- X-Ray shown below

X-RAY

Questions

- What do the clinical appearances suggest?
- What does the x-ray show?
- What other investigations does she require?
- How would you manage this patient?

- . A full vascular examination should be carried out and ankle–brachial indices
- measured. All areas of the foot, especially between the toes and the heel should be examined for
- other areas of ulceration, and the foot examined for the presence of diabetic neuropathy.
- Investigations should include:
- • Full blood count
- • Renal function and C-reactive protein
- • Blood sugar
- • Foot x-ray
- The patient should be commenced on intravenous broad-spectrum antibiotics and an insulin
- sliding scale. The priority is to release the pus and debride necrotic tissue. The x-ray changes
- (osteopenia, osteolysis, sequestra and periostial elevation) suggest there is underlying osteomyelitis
- This will also need to be debrided in order to remove all the infection.
- O steomyelitis in the metatarsophal joint
- A duplex scan or intra-arterial angiogram should then be carried out to ascertain whether the
- blood supply to the foot is compromised and whether any revascularization procedure is necessary.
- As a rule, revascularization should be carried out prior to any surgical debridement/amputation
- in order to ensure that the blood supply is adequate for tissues to heal. In this particular
- case, however, delaying surgery would result in further damage to the foot. Revascularization
- of the foot should be carried out as soon as possible after surgery.
- KEY POINT
- Diabetic feet are at risk of ischaemia (progressive distal ischaemia) and neuropathy
- (sensory, motor and autonomic), and are more prone to infections.

Cont..

- The x-ray changes
- (osteopenia, osteolysis, sequestra and periostial elevation) suggest there is underlying osteomyelitis
- This will also need to be debrided in order to remove all the infection.

A duplex scan or intra-arterial angiogram should then be carried out to ascertain whether the blood supply to the foot is compromised .

Surgical debridement/amputationin order to ensure that the blood supply is adequate for tissues to heal.

- KEY POINT
- Diabetic feet are at risk of ischemia (progressive distal ischemia) and neuropathy (sensory, motor and autonomic), and are more prone to infections.

Diabetic Foot Examination

- **D** deformity
- **I** infection
- **A** atrophic nails
- **B** breakdown of skin
- **E** oedema
- **T** temperature
- **I** ischemia
- **C** callosities
- **S** skin colour

Approach to diabetic foot ulcer

According to ulcer stage

0 At-risk foot, no ulceration : Patient education, accommodative footwear, regular clinical examination

1 Superficial ulceration, not infected :Offloading with total contact cast (TCC), walking brace, or special footwear

2 Deep ulceration exposing tendons or joints : Surgical debridement, wound care, offloading, culture-specific antibiotics

3 Extensive ulceration or abscess : Debridement or partial amputation, offloading, culture-specific antibiotics

Foot Inspection For :

- Deformity
- ulcers
- hammer toes
- loss of archers
- Charcot foot
- Texture of skin
- Integrity of skin
- Texture of nails
- Quality of subcutaneous tissue
- Presence of hair

Investigations

- Bloodwork for high BS, DKA, hyperosmolar state…..
- Gram staining and culture
- Imaging
  - Plain X-ray
  - MRI ?
  - Doppler – Angiogram
  - US? For deep abscess
  - Doppler and ABI

Calculating the ABI

Right Leg ABI

$$= \frac{\text{Higher right-ankle pressure (DP or PT pulse)}}{\text{Higher arm pressure (of either arm)}}$$

Left Leg ABI

$$= \frac{\text{Higher left-ankle pressure (DP or PT pulse)}}{\text{Higher arm pressure (of either arm)}}$$

ABI Interpretation

≤ 0.90 is diagnostic of peripheral arterial disease

Hiatt WR. *N Engl J Med.* 2001;344:1608-1621.

PRINCIPLE OF TREATMENT

- Good glycaemic control
- Treatment of infections
- Wound care
- Offloading to take pressure off the wound
- Early surgical intervention /multidisciplinary approach
- Early diabetic foot education

Off Loading

CUSTOM ORTHOTIC DESIGN

What is "Offloading"?

Offloading is the action of removing force from an area of high pressure. Excess pressure is often a cause of diabetic foot ulcers and by removing the pressure, we can allow the ulcer to heal.

www.customorthotic.ca

WOUND DEBRIDEMENT

- Debridement of **nonviable tissue** a must!
- Devitalized tissue **doesn't bleed** when it is scrubbed and **appears blue/black**
- Devitalized tissue acts as **anaerobic medium** and inhibits **leukocyte phagocytosis** (decreases wound's resistance to infx)
- Goal is to **reestablish a margin** of normal tissue and wound edges (elliptical area around wound)

RAY AMPUTATION

- Tennis-racket - a straight incision along the dorsal surface metatarsal bone with circumferential incision around the base of the toe.
- Goal- to save all available viable skin on the toe
- The incision down to the bone to prevent damage to the digital vessels laterally
- The metatarsal bone is transected across the shaft

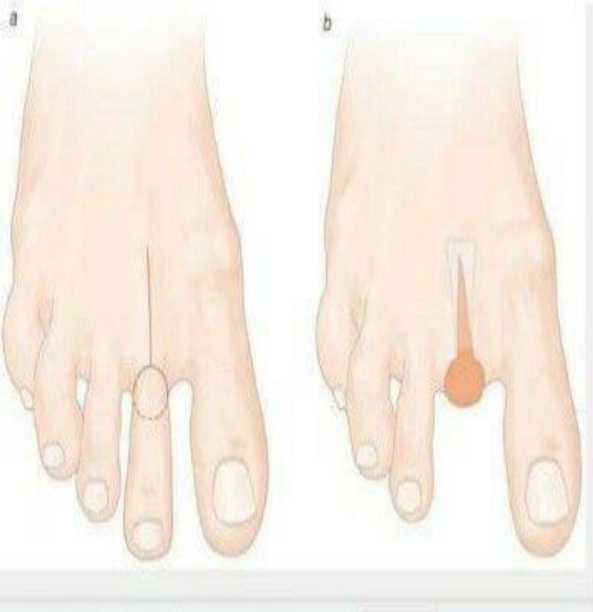

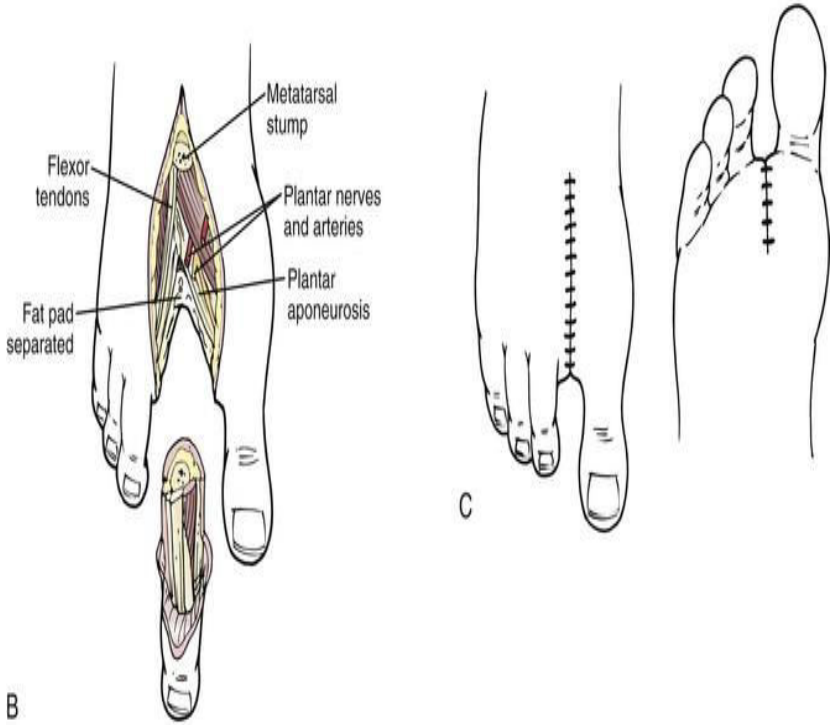

AMPUTATION OF FOOT:

- TOE AMPUTATION OR DISARTICULATION
- METATARSAL PHALANGEAL DISARTICULATION
- TRANSMETATARSAL AMPUTATION
- LISFRANC AMPUTATION
- CHOPART AMPUTATION
- SYME AMPUTATION
- BOYD'S AMPUTATION

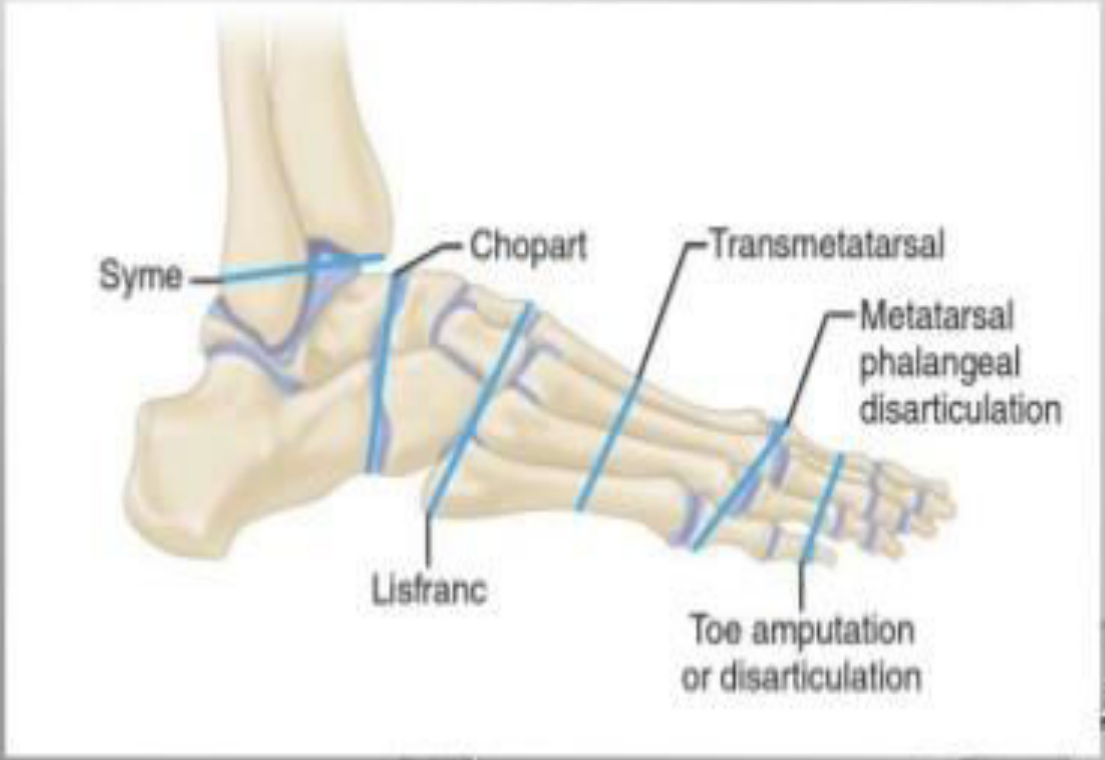


GOOD JOB

6: testicular pain

- ***History***
- A 16-year-old boy attends the emergency department complaining of sudden onset of right testicular pain. The pain woke him from his sleep and has persisted over the last 3 h. His mother says that he has vomited once. His previous medical history includes a similar event a year ago, but on that occasion the pain subsided quickly.

Examination

- On examination the left hemi-scrotum feels normal but the right side is acutely swollen and tender on palpation. The testicle is elevated when compared to the other side and has an abnormal horizontal lie. The abdomen is soft and non-tender. His blood pressure is 130/84 mmHg and the pulse rate is 110/min. The cremasteric reflex is absent.

Questions

- What is the diagnosis?
- What should you consider in the differential?
- What is the management in this case?

ANSWERS

- This boy has testicular torsion until proven otherwise.
- Testicular torsion is actually torsion of the spermatic cord and not of the testis.
- This results in irreversible ischemia to the testicular parenchyma, which can occur within 4–6 h of cord torsion.
- The presentation can vary and includes vague loin or groin pain as well as scrotal signs and symptoms.
- There maybe a history of excessive physical activity or trauma. Testicular torsion can occur at any age
- but commonly has a bimodal distribution. There is a small peak in the first year of life but is
- more common between late childhood (post puberty) and early adulthood, i.e. 12–18 years.
- .

ETEIOPATHOGENSIS

- Normally, the tunica vaginalis envelops the body of the testis and only part of the epididymis(which is usually fixed), and the testis is unable to twist.
- In cases of torsion, there is an abnormal amount of free space between the parietal and visceral layers of the tunica vaginalis, which encompasses the testis, epididymis and the cord for a variable distance. This free space allows the now hypermobile testis and epididymis to rise in the scrotum and twist. This accounts for the (‘bell clapper deformity’).
- If the presentation is delayed, an acute hydrocoele may develop making examination difficult, and the scrotum may appear erythematous. Surgical exploration is essential if torsion is considered.
- Testicular salvage rates are directly correlated with the number of hours after the onset of pain with a significant drop off after 6 h. Urinalysis is often negative and the diagnosis should
- be made clinically.

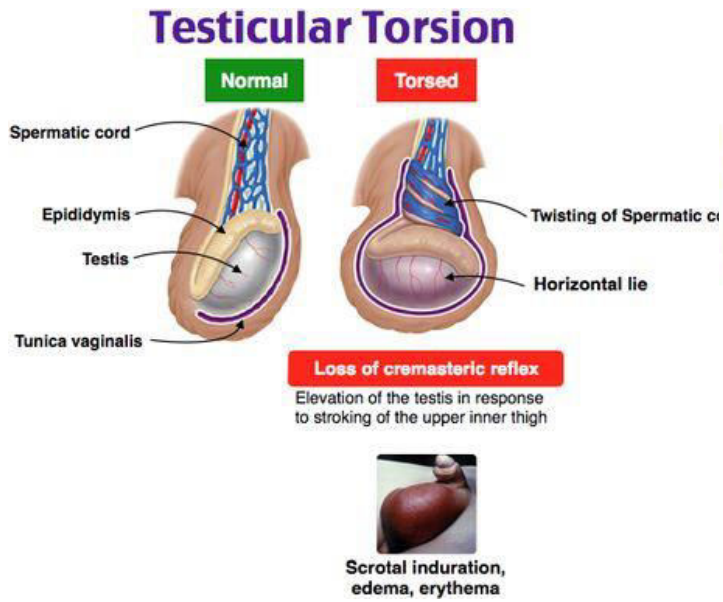

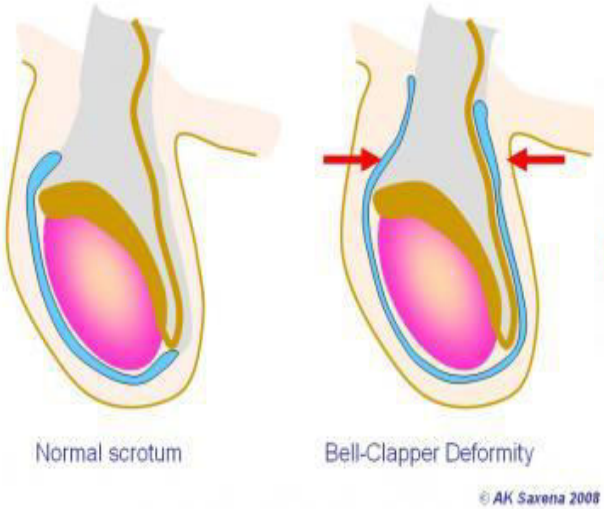

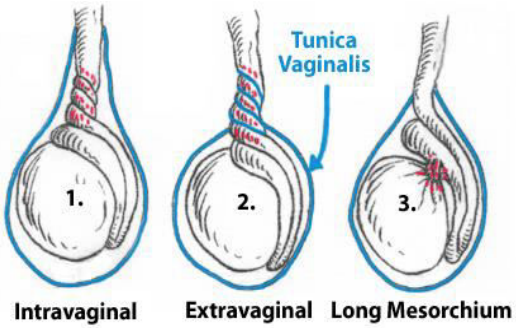

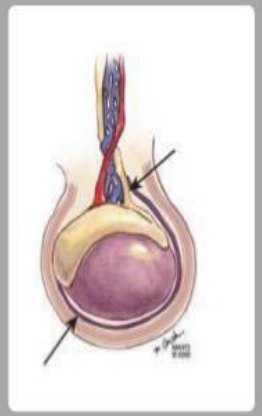

Types

1-Extravaginal Torsion:

- Most often occurs in newborns without the "bell clapper" deformity.
- Poor/absent attachment of testis to scrotal wall ⇒ Rotation of testis + epididymis + tunica vaginalis as a unit and causing torsion of the cord at the level of the external ring

TWO TYPES OF TESTICULAR TORSION

Intravaginal torsion

Is the more common type, occurring most frequently at puberty. It results from anomalous suspension of the testis by a long stalk of spermatic cord, resulting in complete investment of the testis and epididymis by the tunica vaginalis.

- This anomaly has been likened to a bell-clapper

Differential diagnoses

- Torsion of the appendix testis
- Torsion of the appendix epididymis
- Epididymo-orchitis
- Infected hydrocoele
- Testicular rupture
- Strangulated inguinal hernia
- A bleed into a tumour
- In torsion of the appendix testis, the tenderness is usually localized above the upper pole of
- the testis and may be accompanied by the 'blue dot' sign, which represents necrosis in the
- appendix. Hydrocoeles may be tender if large and will transilluminate. If a patient is suspected
- of having epididymo-orchitis, the urine should be screened for infection. There may
- Also be a history of urethral discharge or urinary symptoms such as frequency or dysuria
- If testicular torsion is suspected, surgical exploration should be carried out as soon
- as possible.
- Testicular salvage rates decline significantly after 6 h from the onset of testicular
- pain.

MANAGEMENT

Testicular Torsion

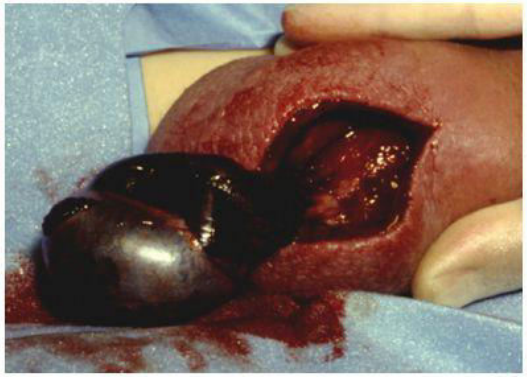

Investigations:

- Color Doppler US
- Radionuclide Scan

Management:

- Timing is critical 4 - 6 hours
- Exploration if any doubt
- Untwist (open book) and assess viability
- Fix the other side
- If more than 12 hours, it is likely to be non-viable and may need orchiectomy


Well
Done!

7: Abdominal trauma

- ***History***
- You are called urgently to the resuscitation room for a trauma call. An 18-year-old girl has fallen from her horse. During her descent, the horse kicked her, and she is now complaining of generalized abdominal pain and left shoulder-tip pain.
- ***Examination***
- She is talking and examination of her chest is normal. The oxygen saturations are 100 percent on 24 per cent oxygen. Initially, her pulse rate is 110/min with a blood pressure of 84/60 mmHg. She is slightly drowsy and her Glasgow Coma Score (GCS) is 14. On examination of the abdomen, there is an abrasion on the left side beneath the costal margin with tenderness in the left upper quadrant. There is no evidence of any other injuries and the urinalysis is clear. The patient is given 2 L of intravenous fluids and the blood pressure improves to 130/90 mmHg. As the patient has now become stable, a CT scan of the chest and abdomenis obtained. The CT image is shown below

CT SCAN

Clinical presentation

- On returning to the emergency department, the patient becomes increasingly agitated. The
- nurse informs you that her blood pressure is now 80/60 mmHg and the pulse rate is 130/min.

Questions

- What does the CT scan show?
- Are there any alternative investigations to CT?
- What special requirements may this patient have postoperatively?

Diagnosis

Splenic Trauma

- Diagnosis:
  - Plain abdominal film
    - Unreliable and nonspecific
    - Triad of radiographic findings in acute splenic rupture
      - Left diaphragmatic elevation
      - Left lower lobe atelectasis
      - Left pleural effusion

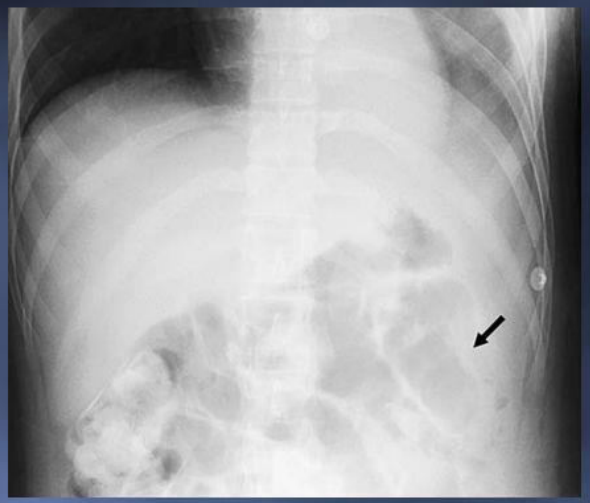

Radiograph demonstrates a left pleural effusion, left basilar atelectasis, and inferomedial displacement of the splenic flexure (arrow)

FAST

Splenic Trauma

- Diagnosis:
  - FAST
    - Focused Abdominal Sonography for Trauma
    - Bedside study for unstable patient
    - 15% false-negative
    - May miss up to 25% of liver and spleen injuries
    - Compared to CT only 63% sensitive for detecting free fluid

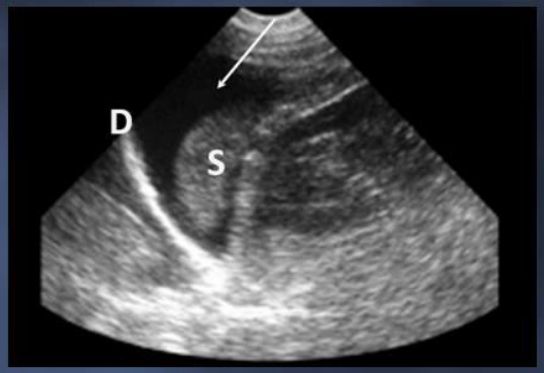

Fluid in the subphrenic space and splenorenal recess can be detected. The image shown demonstrates blood (arrow) between the spleen (S) and diaphragm (D).

ANSWERS

- The patient has sustained a tear to the splenic capsule, causing intraperitoneal bleeding. The CT scan shows the fractured spleen with surrounding hematoma.
- The shoulder-tip pain described is known as Kehr's sign, and is indicative of blood in the peritoneal cavity causing diaphragmatic irritation.
- Unstable patients suspected of splenic injury and intra-abdominal haemorrhage should undergo exploratory laparotomy and splenic repair or removal.
- Blunt trauma, with evidence of hemodynamic instability that is unresponsive to fluid challenge, should be considered a life-threatening solid organ (splenic) injury.
- Those patients who respond to an initial fluid bolus, only to deteriorate again with a drop in blood pressure and increasing tachycardia, are also likely to have a solid organ injury with ongoing haemorrhage.

FAST

- Transfer to the CT scanner can be extremely dangerous for an unstable patient.
- Focused abdominal sonographic technique (FAST) is helpful in diagnosing the presence or absence of blood in the peritoneal cavity without transfer to a CT scanner.
- Diagnostic peritoneal lavage may be a valuable adjunct if time permits and multiple other injuries are present.
- In a haemodynamically stable trauma patient, CT scanning provides an ideal non-invasive method for evaluating the spleen. The decision for operative intervention is determined by the grade of the injury and the patient's current or pre-existing medical conditions.
- Splenic embolization is a safe alternative depending on the grade and location of the splenic injury.
- Those patients who undergo splenectomy have a lifetime risk of septicaemia and should receive immunizations against *pneumococcus, haemophilus and meningococcus.*

USG VS CT

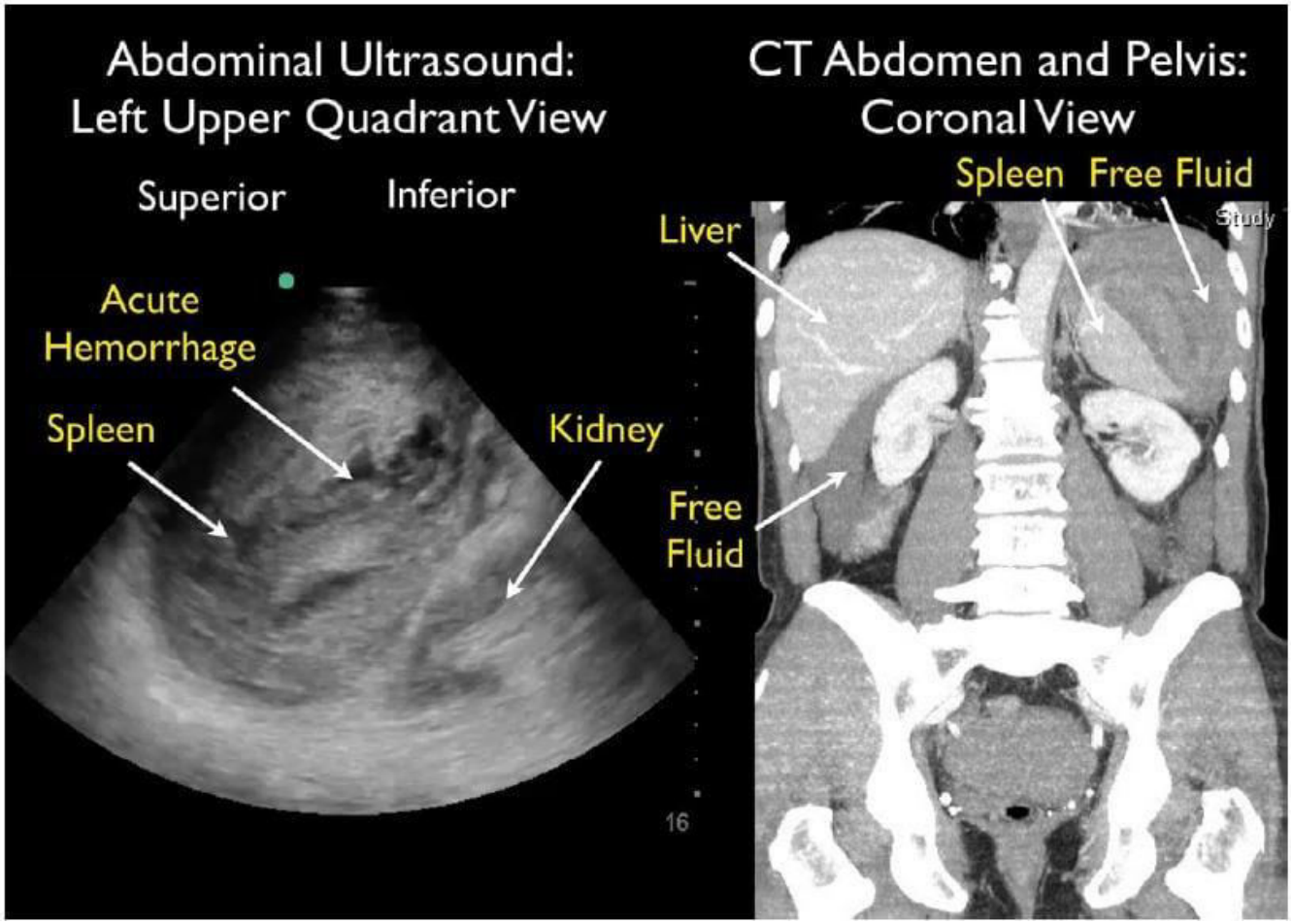
Abdominal Ultrasound:
Left Upper Quadrant View
Superior
Inferior
Acute Hemorrhage
Spleen
Kidney
16
CT Abdomen and Pelvis:
Coronal View
Spleen
Free Fluid
Liver
Free Fluid
Study

Splenic Trauma

- Diagnosis
  - Injury should be suspected in blunt upper abdominal injuries (MVA and Bike)
  - Injuries are often associated with fractured ribs of the left chest
  - Splenic injuries can cause extensive and continued hemorrhage, others can cause subcapsular hematomas that are subject to rupture at any time
  - If splenic injury is suspected, admission to the hospital for monitoring is mandatory
  - The signs and symptoms of splenic trauma are those of hemoperitoneum (generalized LUQ pain)

Treatment of Ruptured Spleen

- Splenic preservation operations
- Partial splenectomy
- Capsular repair
- Non operative treatment

Complications

Complications of Splenectomy

A. **Immediately postoperative:**

- Peripheral Blood changes
  - Leukocytosis
  - Thrombocytosis
  - Presence of Howell-Jolly bodies
- Hemorrhage
- Atelectasis (left lower lobe, most common)
- Subphrenic Abscess or hematoma
- Pancreatitis or pancreatic fistula (as a result from parenchymal manipulation)


WELL DONE!
shutterstock.com • 415603990

8.TRAUMA

- History
- You are asked to review a 78-year-old man on the observation ward. He was admitted the previous evening with confusion. Earlier in the evening a friend visited and reported that he had fallen over 3 weeks ago and had become increasingly confused and clumsy.
- He takes a calcium antagonist for essential hypertension and aspirin since a previous heart attack. He lives alone and is independent and self-caring. He is a non-smoker, but there had been concerns over his increasing alcohol intake following the death of his wife 5 years ago.
- Examination
- He has a normal temperature with a pulse rate of 78/min and a blood pressure of 136/86 mmHg. The cardio respiratory and abdominal systems appear normal. He is confused in time, place and person. His pupils are symmetrical and reactive. The rest of his cranial nerve and peripheral
- neurological examinations are normal.

CT SCAN BRAIN

Questions

- What investigation is shown, and what is the diagnosis?
- Which factors in the history make you suspicious of this diagnosis?

CSDH

- This man has a chronic subdural haematoma (CSDH) shown on a CT scan .
- This condition is twice as common in men as women.
- Risk factors: Chronic alcoholism, epilepsy, anticoagulant therapy (including aspirin) and thrombocytopenia.
- CSDH is more common in elderly patients due to cerebral atrophy. It is thought that cortical bridging veins are put under tension as the brain gradually shrinks away from the skull. This patient has had a minor head injury in the preceding weeks, causing one of these cortical veins to tear. The history of potential alcohol abuse and aspirin use also contribute to the bleeding risk.
- Slow bleeding from the low-pressure venous system often allows a large haematoma to form before clinical signs become evident.
- Initial misdiagnosis is, unfortunately, quite common.

CSDH

- Before the advent of CT
- CSDH was known as the ‘great imitator’ as it was often mistaken for dementia, transient
- ischaemic attacks or strokes.
- The CT findings for subdural haematomas change with time.
- In the first week, the blood is hyperdense compared to brain tissue.
- In the second and third weeks, the haematoma appears isodense compared to brain tissue; and after the third week, the blood appears hypodense compared to brain tissue.
- ***The term ‘chronic' is applied to subdural hematomas that are older than 21 days***. When there is no clear history of a head injury (25–50 per cent of patients), the diagnosis can be made radiologically according to the CT appearances of the blood.
- Once the diagnosis is made, the liquefied blood can be drained via one or two Burr holes.
- Even for patients with significant comorbidities, operative intervention is not contraindicated
- as this procedure can be performed under local anaesthetic. Eighty per cent of patients
- will return to their previous level of function.

9: assessment of a breast lump

- History
- A 47-year-old female presents to the breast clinic complaining of a painful lump in her left breast. She has not noticed any nipple discharge, skin changes or changes in her breast shape.
- Her mother was diagnosed with breast cancer at 50 years of age. She is married and has no children. No other health issues
- Examination
- A 4-cm irregular lump is found adjacent to the nipple in the left breast. The lump is hard in consistency and only mildly tender on palpation. It is slightly mobile with no tethering of the overlying skin. It does not appear deeply fixed. There are palpable left-sided axillary lymph nodes which are mobile. The right breast and axilla are normal. Abdominal and skeletal examination normal

Questions

- How should this lump be assessed?
- What are the risk factors for

Developing breast cancer?

- To what age group does

a breast screening programme offered?

- What is a sentinel lymph node

biopsy?

Mammogram.

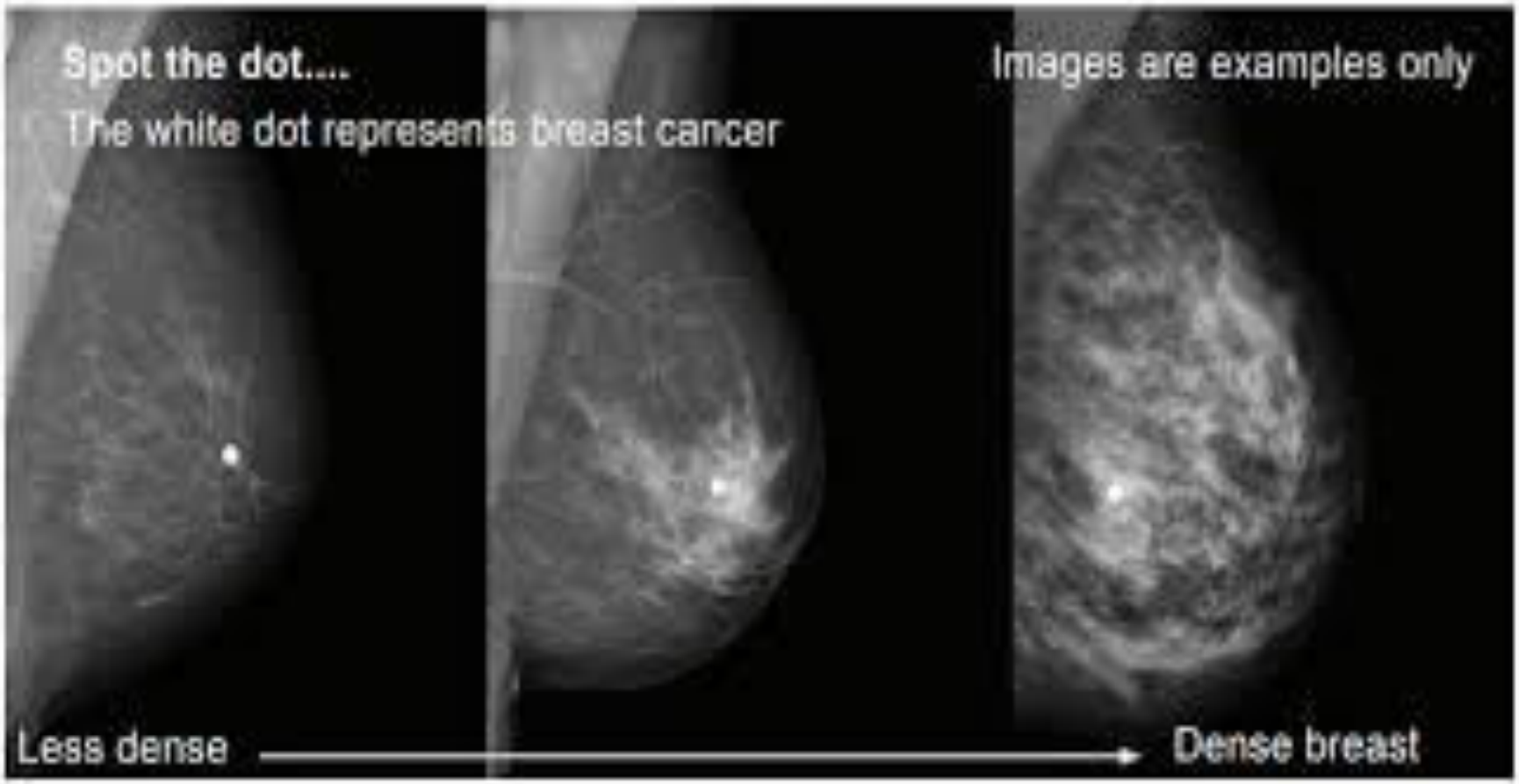
Spot the dot....
The white dot represents breast cancer
Images are examples only
Less dense
Dense breast

Mammogram

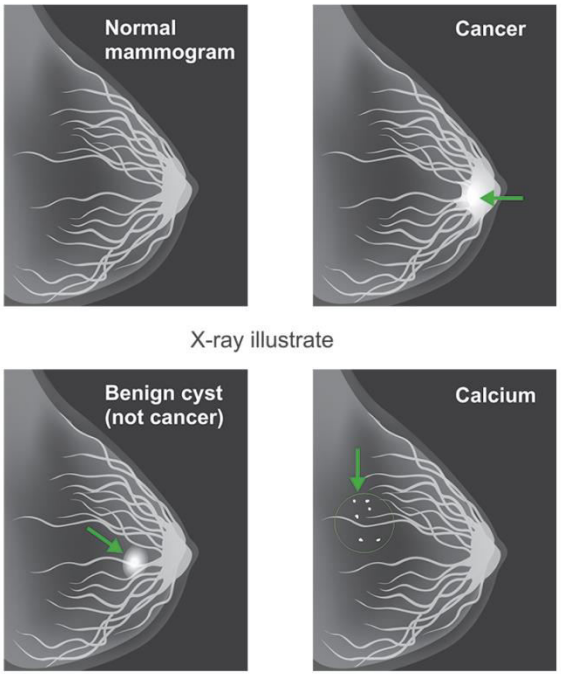

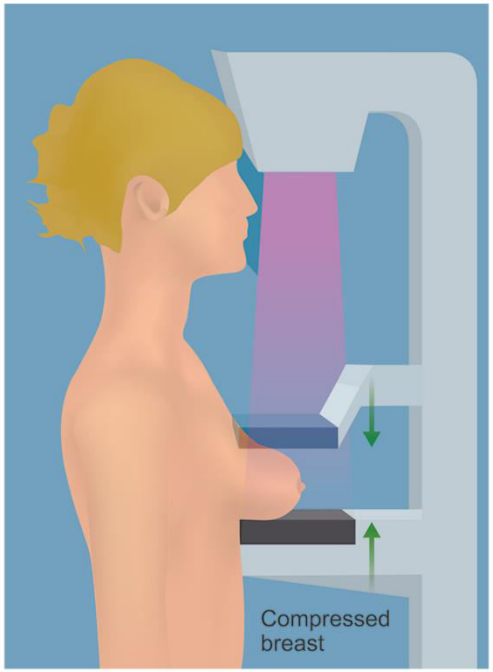

- In mammography, each breast is compressed horizontally.
- During a screening mammogram, the breast is placed between two plastic plates.
- The plates then are briefly compressed to flatten the breast tissue.
- Two views usually are taken of each breast.

VIEWS

Mammography Views

Basically there are 2 main views.

- Craniocaudal view (RCC and LCC)
- Mediolateral oblique (RMLO and LMLO)

RCC

LCC

RMLO

LMLO

RISK FACTORS

- The incidence increases with age, but at menopause the rate of increase slows.
- Risk factors for developing breast cancer include:
- Estrogen exposure, unopposed by progesterone
- Nulliparous women in developed countries
- Mutations in the *BRCA1 and BRCA2 genes*
- Early menarche/late menopause
- Family history
- Saturated dietary fats
- Previous benign atypical hyperplasia

ANSWERS

Triple assessment

Clinical examination

Radiology

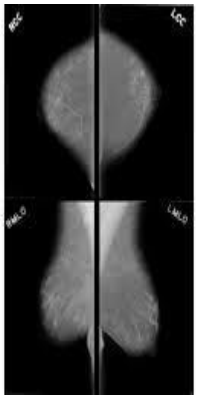

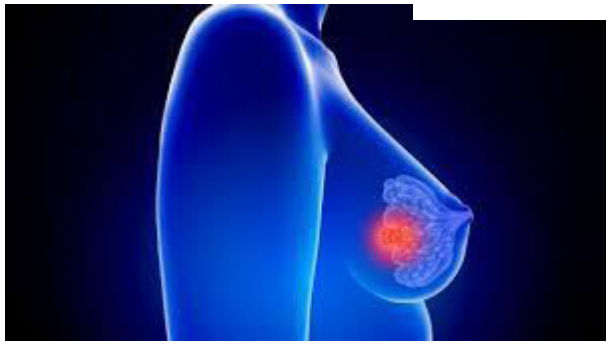

Pathology

CNB

L.B

MANAGEMENT

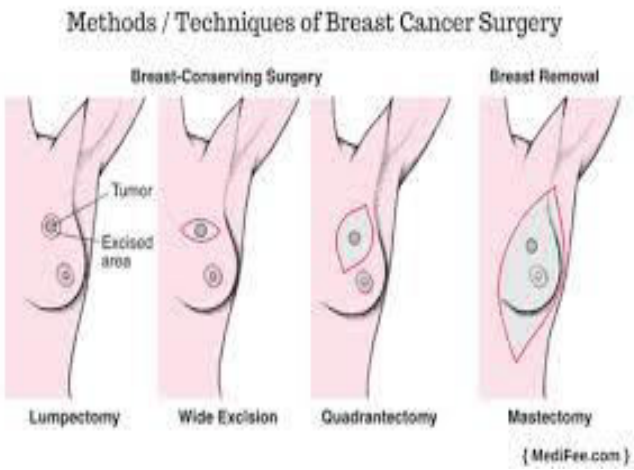
Methods / Techniques of Breast Cancer Surgery
Breast-Conserving Surgery
Breast Removal
Tumor
Excised area
Lumpectomy
Wide Excision
Quadrantectomy
Mastectomy
{ MediFee.com }

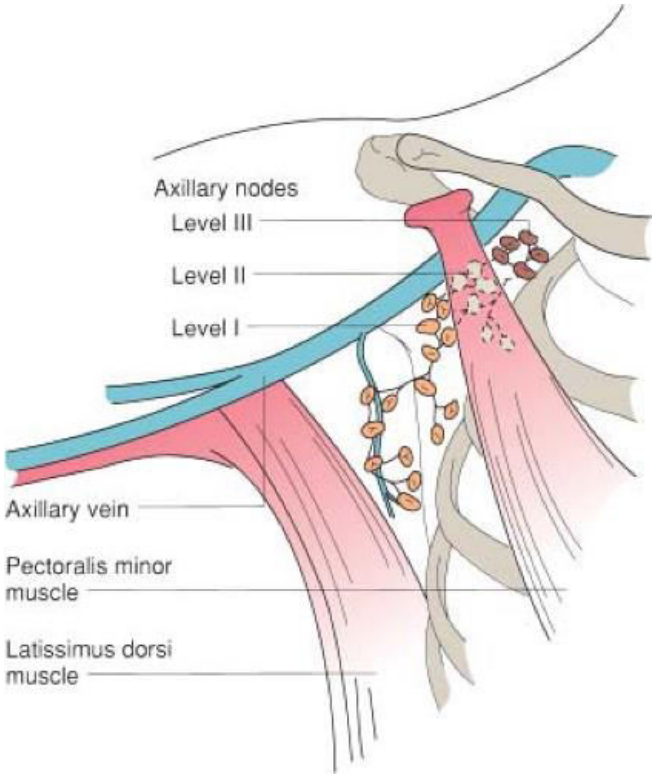
Axillary nodes
Level III
Level II
Level I
Axillary vein
Pectoralis minor muscle
Latissimus dorsi muscle

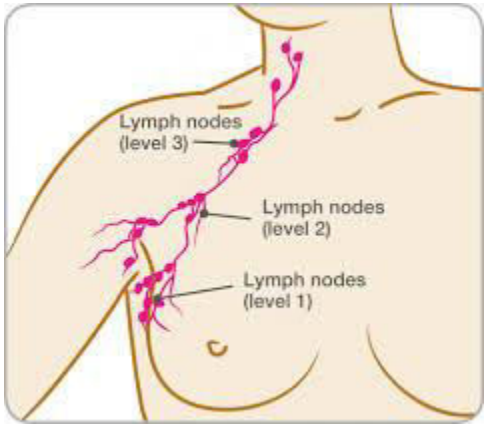
Lymph nodes (level 3)
Lymph nodes (level 2)
Lymph nodes (level 1)

Sentinel node Biopsy

Introduction of the Sentinel Lymph Node Biopsy for Breast Cancer

- First described by Morton in 1992 for melanoma
- Applied to breast cancer in 1994 by Giuliano, et al
- Identification and evaluation of the sentinel lymph node allows for avoidance of complete axillary lymph node dissection in node negative patients

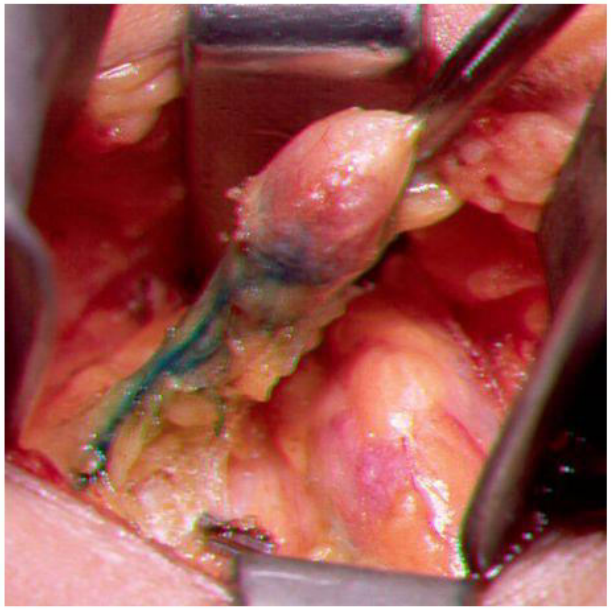

SNB

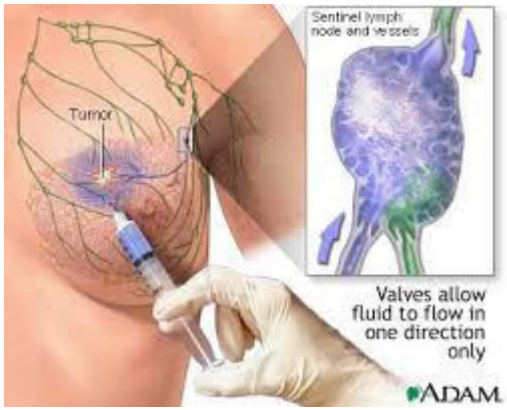

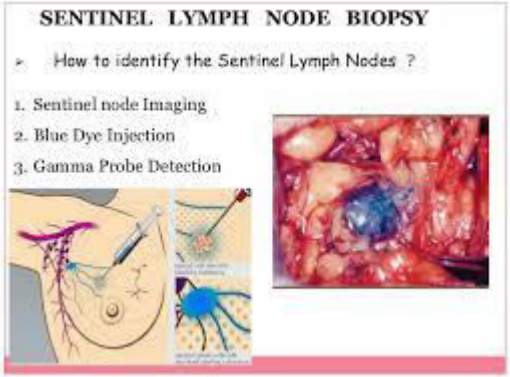

radiocolloidTc99

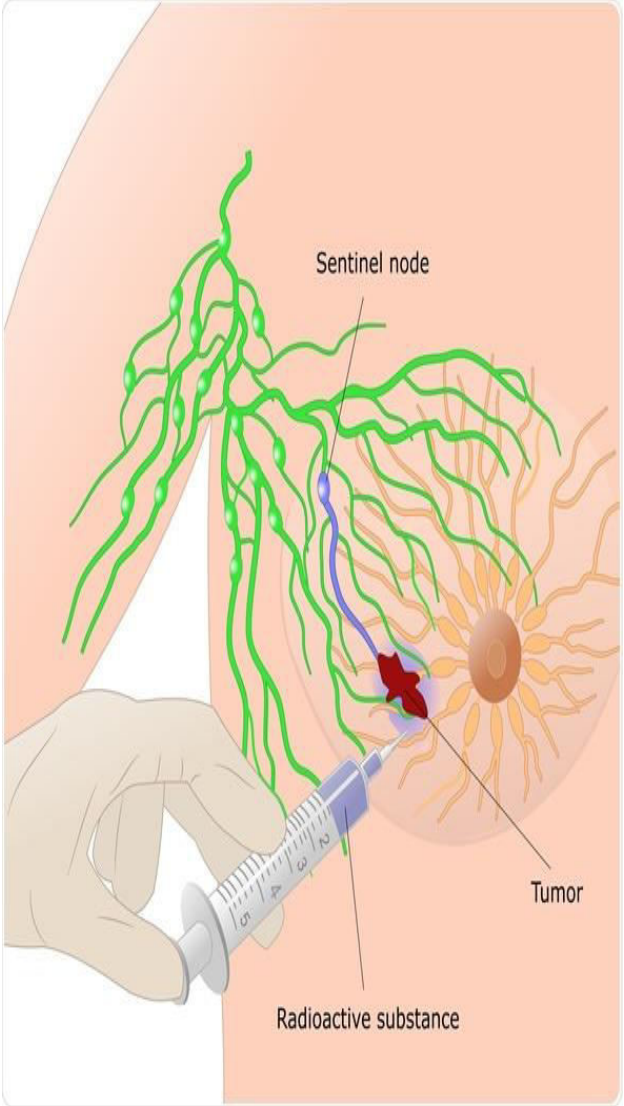

Screening

- offered to women between the ages of 40 and 70 years. All women now have two views of the breast taken at every screen – craniocaudal and mediolateral views. It has reduced mortality rates in the 55–69-year age group.
- In patients without systemic disease, surgery is potentially curative.
- Treatment options
- Mastectomy or breast-conservation surgery, such as wide local excision or quadrantectomy.
- Axillary lymph node status is a good prognostic indicator for breast cancer and is

helpful in delineating further treatment pathways.

Management of the axilla is controversial.

- Options include axillary node sampling, clearance or sentinel node biopsy.
- The sentinel node Biopsy: is the first lymph node the breast lymphatics drain to before reaching the axilla. Sentinel
- lymph node biopsy is an alternative to axillary sampling or clearance, which provides information on the probable tumour status of other axillary lymph nodes.
- Technique
- injection of a technetium-based radioisotope into the breast, often in combination with a dye.
- The sentinel node is detected with the use of a gamma camera or direct visualization on dissection
- (the dye is usually blue) before excision.

Now this is just too awesome!!

ありがとうございます